



Case Report

Volume 3 Issue 2 – February 2017
DOI: 10.19080/ARGH.2017.03.555610

Adv Res Gastroentero Hepatol

Copyright © All rights are reserved by Zaheer Nabi

Unusual Cause of Dysphagia in a Middle Age Male



Zaheer Nabi^{1*}, Radhika Chavan¹, Anuradha Sekharan² and D Nageshwar Reddy¹

¹Consultant gastroenterologist, Asian Institute of Gastroenterology, India

²Consultant Pathologist, Asian Institute of Gastroenterology, India

Submission: January 19, 2017; **Published:** February 23, 2017

*Corresponding author: Zaheer Nabi, Asian Institute of Gastroenterology, 6-3-661, Somajiguda, Hyderabad, India, Tel: +91 40 23378888; Email: anukaku08@gmail.com

Abstract

Dysphagia is not uncommon in gastroenterology practice. The differential diagnosis is wide and includes both mechanical and motility causes. Esophageal lichen planus is uncommon but now increasingly recognized. It occurs in more than half of cases of lichen planus with muco-cutaneous involvement. Often there is a delay in diagnosis and subsequent treatment. The endoscopic picture of esophageal lichen planus closely mimics that of eosinophilic esophagitis. However, histological picture is entirely different and useful for differentiating between the two. We present here a challenging case where characteristic oral lesions provided with the first clue to the diagnosis of esophageal lichen planus. Subsequent histo-pathological findings were characteristic and confirmed the diagnosis.

Keywords: Dysphagia; Endoscopy; Lichen planus

Introduction

Lichen planus is a well-recognized chronic idiopathic disorder involving the skin, nails and mucosal surfaces including the mouth, pharynx and perineum. Mucosal surface involvement is found in about 30%-70% of patients diagnosed with lichen planus [1]. Oesophageal involvement is rare and its true prevalence is unknown. In this case report we describe a middle aged gentleman presenting with symptoms of gastroesophageal reflux disease and diagnosed as oesophageal lichen planus on complete evaluation.

Case Report

A 44-year-old man presented with heartburn, occasional pain and difficulty in swallowing solid foods for 3 years. There was increase in severity of symptoms for last 1 year during which he lost about 8kgs weight. There was no relief of symptoms with antacids or proton pump inhibitors. There was no past history of asthma, atopy or allergy. Oral examination revealed white reticulated lesion with erosions and hyperemia over the mucosa of hard palate (Figure 1). There were no skin lesions. Upper gastrointestinal endoscopy showed erythematous esophageal mucosa with few small ulcers, rings/web and whitish curd

like deposits (Figure 2a & 2b) involving predominantly upper and mid esophagus. Histopathology of the esophageal lesions revealed ulceration, dense band like infiltrate of neutrophils in subepithelium, civatte bodies and subepithelial separation suggestive of esophageal lichen planus (Figure 3a & 3b). He was initially treated withswallowed fluticasone for 4 weeks, but there was no symptomatic relief. Subsequently he was started on oral steroids in tapering fashion. There was significant clinical improvement and follow up endoscopy at 4 weeks revealed healing of esophageal lesions.

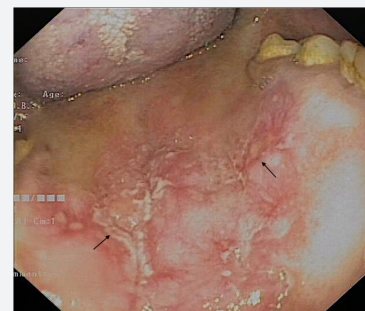


Figure 1: White reticulated lesion with erosions and hyperemia over the mucosa of hard palate.

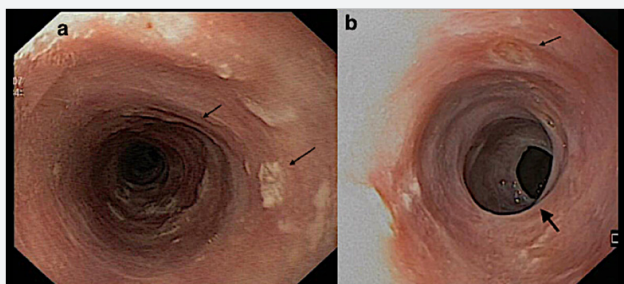


Figure 2a & 2b: Upper gastrointestinal endoscopy showing erythematous esophageal mucosa with few small ulcers, rings/web and whitish curd like deposits (arrows).

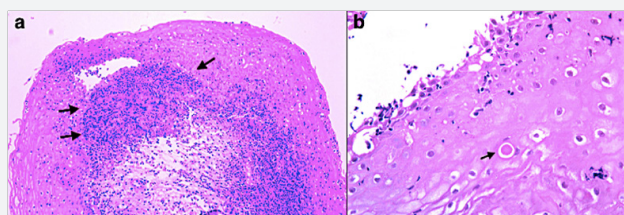


Figure 3 a: Low power histo-pathological image revealing ulceration, dense band like infiltrate of neutrophils in subepithelium, and subepithelial separation.

Figure 3b: High power microscopic view showing Civatte bodies suggestive of esophageal lichen planus.

Discussion

Esophageal lichen planus is considered to be rare. However, the true prevalence of lichen planus esophagitis among patients with oral lichen planus may have been underestimated because of subtle clinical findings and lack of characteristic histological features. In a recent study, chromoendoscopy was used to determine the prevalence of esophageal involvement in patients with oro-cutaneous lichen planus. Up to 50% of patients with oro-cutaneous lichen planus had esophageal involvement [2]. In another study, esophageal involvement was found in about 60% cases with LP of the skin, hair, nails, oral mucosa, and/or genital mucosa [3]. Early recognizing of esophageal involvement is necessary to prevent development of strictures [4]. Also several case reports have described the development of squamous cell carcinoma in these patients [5,6]. However, the optimal surveillance interval is not known in these patients.

Most of the described cases in literature are middle aged females. Clinically patients may be asymptomatic or present with dysphagia and odynophagia. Endoscopically there may be

inflamed friable mucosa, webs, pseudomembranes, erosions, ulcerations or even strictures in late cases. Clinical and endoscopic picture of esophageal lichen planus may mimic that of eosinophilic esophagitis. Histological features in esophageal lichen planus include band like or lichenoid lymphocytic infiltrate involving the superficial lamina propria and basal epithelium, basal keratinocyte degeneration which often include Civatte bodies (necrotic keratinocytes with anucleate remnants) [7]. Unfortunately, there is no standard treatment for oesophageal lichen planus. However, early treatment may prevent formation of strictures.

Treatment options based on previous reports include swallowed fluticasone, oral steroids or other immunosuppressants like tacrolimus and cyclosporine [8]. In a recent report, topical swallowed budesonide or fluticasone was effective for oesophageal lichen planus [9].

References

- Shenfine J, Preston SR (2006) Lichen planus in the oesophagus: are we missing something? *Eur J Gastroenterol Hepatol* 18(10): 1043-1045.
- Quispel R, van Boxel OS, Schipper ME, Sigurdsson V, Canninga-van Dijk MR, et al. (2009) High prevalence of esophageal involvement in lichen planus: a study using magnification chromoendoscopy. *Endoscopy* 41(3): 187-193.
- Kern JS, Technau-Hafsi K, Schwacha H, Kuhlmann J, Hirsch G, et al. (2016) Esophageal involvement is frequent in lichen planus: study in 32 patients with suggestion of clinicopathologic diagnostic criteria and therapeutic implications. *Eur J Gastroenterol Hepatol* 28(12): 1374-1382.
- Rauschecker AM, Levine MS, Whitson MJ, Tondon R, Rubesin SE, et al. (2017) Esophageal Lichen Planus: Clinical and Radiographic Findings in Eight Patients. *AJR Am J Roentgenol* 208(1): 101-106.
- Schwartz MP, Sigurdsson V, Vreuls W, Lubbert PH, Smout AJ, et al. (2006) Two siblings with lichen planus and squamous cell carcinoma of the oesophagus. *Eur J Gastroenterol Hepatol* 18(10): 1111-1115.
- Calabrese C, Fabbri A, Benni M, Areni A, Scialpi C, et al. (2003) Squamous cell carcinoma arising in esophageal lichen planus. *Gastrointest Endosc* 57(4): 596-599.
- Chandan VS, Murray JA, Abraham SC (2008) Esophageal lichen planus. *Arch Pathol Lab Med* 132: 1026-1029.
- Donnellan F, Swan MP, May GR, Kandel G, Marcon NE, et al. (2011) Fluticasone propionate for treatment of esophageal lichen planus. A case series. *Dis Esophagus* 24(4): 211-214.
- Podboy A, Sunjaya D, Smyrk TC, Murray JA, Binder M, et al. (2017) Oesophageal lichen planus: the efficacy of topical steroid-based therapies. *Aliment Pharmacol Ther* 45(2): 310-318.



This work is licensed under Creative Commons Attribution 4.0 License
DOI:10.19080/ARGH.2017.03.555610

**Your next submission with JuniperPublishers
will reach you the below assets**

- Quality Editorial service
- Swift Peer Review
- Reprints availability
- E-prints Service
- Manuscript Podcast for convenient understanding
- Global attainment for your research
- Manuscript accessibility in different formats
(Pdf, E-pub, Full Text, audio)
- Unceasing customer service

Track the below URL for one-step submission

<https://juniperpublishers.com/online-submission.php>